

Case Report

Homeopathic Management in PUPPS

Aishwarya Shankar Gandalwar*

Guru Mishri Homoeopathic Medical College and Hospital, Shelgaon, Jalna

ABSTRACT

Pupps is short form of pruritic urticarial papules & plaque of pregnancy. Also known by PUPPS. It is also known as polymorphic eruption of pregnancy or PEP. It's a rash that starts OFF unobtrusive enough and begin as tiny, itchy red bumps in the stretch marks on the abdomen. The author present a case of PUPPS Pruritus urticarial plaque and papules cured by polychrest remedy.

Keywords: PUPPS, calcarea carb, calendula

Address for Correspondence:

Dr. Aishwarya Shankar Gandalwar

Department of Practice of Medicine

Guru Mishri Homoeopathic Medical College and Hospital, Shelgaon, Jalna

Conflict of Interest: None Declared!

(Received 15 June 2020; Accepted 30 July 2020; Published 23 August 2020) ISSN: 2347-8136 ©2020 JMPI

INTRODUCTION:

Pupps is short form of pruritic urticarial papules & plaque of pregnancy. Also known by PUPPS. It is also known as polymorphic eruption of pregnancy or PEP. It's a rash that starts OFF unobtrusive enough and begin as tiny, itchy red bumps in the stretch marks on the abdomen. Its distinguishing characteristic is that it surrounds but never affect the navel, these red bumps gets bigger & forms large patches and spreads down the legs and up the chest, it is itchy and eczematous rash.

Incidence

PUPPS however is the most common specific skin condition during pregnancy, About one in every 130 to 1 in 300 pregnancies developed this rash, It more likely to occur in a first pregnancy, but can sometimes occur in subsequent ones.

Clinical Feature

1. Itchy red bumps.
2. Start on the abdomen, then spreads.
3. Red, Eczema like patches.
4. Severe itching.
5. Blisters

Causes

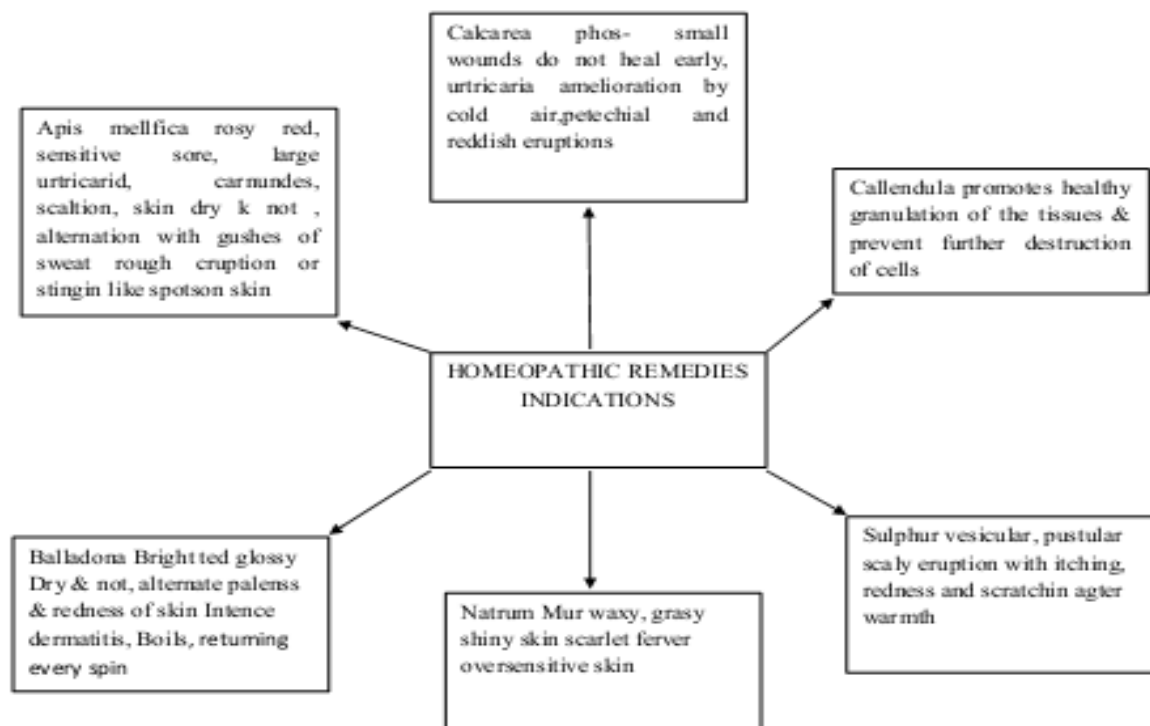
1) **An organ system in overtaxed:** Since liver the main detox organ of body, when it becomes overwhelmed with toxins, the symptoms are exhibited through the skin through rashes & discoloration. The kidneys are in charge of filtering the body's blood, and us also through to play a potential role in PUPPS rash.

2) **Abdominal stretching that causes skin inflammation:** Carrying extra weight, have multiples or large babies puts extra stress on the skin and damages the connective tissue. It starts out a stretch marks but the damage can cause the skin to be inflamed and develops into PUPPS rash.

3) **Fetal cells migration to the mother skin:** During pregnancy fetal cells migrate to different parts of the mother body, including her. Heart and skin. This can be protective benefits from certain diseases that suggest foreign invaders, triggering a systemic response and causing a PUPPS rash. It is more likely occur if women having boy. In 60-70% of women with PUPPS, who were carrying boys, male DNA was detected in their PUPPS rash.

Prevention: Since no one is really sure what causes PUPPS exactly, there isn't a guaranteed way to prevent it, you can however make some healthy choices that decrease of prevent of getting the condition. Also keep the moisturizing skin by applying moisturizers.

Homoeopathic management



Case study

Chief complaints

1. Reddish papules and plaques on skin, Especially around the stretch marks and below navel and on hands and lower limbs since 7 days.
2. Intense itching and scratching continuously especially in sleeping time.
3. Insomnia due to itching and burning of skin continously .
4. Amelioration after bath and scratching with comb, cold air.
5. Aggravation by dryness.
6. Red papules and itchy skin when sleeping especially in pregnancy.

Appearance

Healthy ,flabby ,beautiful with plethoric face, rhobust women with sensitiveness,very thin lady wearing saree with simplicity.

Education: She studied post-graduation in biochemistry. She was very talented in her school life. Always participates in every activities, cultural, competitive exams and studies.She scored 80% in 12th std. Hence parents are too happy to fulfill her needs. She feels delightful to studies. She always active and never get discourage easily.She is always afraid that anyone scolds her.

Life space

CHILDHOOD - She was brought up her husband .She don't have siblings alone to her parents. Her father is laborer in steel factory and

her mother died when she was in 10 th std after that her father bring her stepmother without informing her. She haven't accepted her step mother by heart till her own marriage. She was depressed due to her mother's death. Her father was too strict which made too silent and sad. Her father had always objections if she spoke to anybody from outside or laugh loudly with anyone. So she never went against her father even she wears dresses of his choice only.

She was with full of imaginations, sees ghosts and spirits and wild things and even of dead body. Dreams of ghost, criminals and dead persons, fearful. Fear of dark 3+, alone when 2+ and fear of animals especially snakes and lizards. **AFTER MARRIAGE-** Patient got married in joint family at the age of twenty-three after completion of post-graduation.

She lived with her in laws and sister in law .But her husband was too careful and respect ful towards her.He always support her in carrier and everything. She always have dreams of ghost, dead animals and screams during dreams.

She has fear of imaginary things, great anxiety and excitement. During her first pregnancy she was happy with this pregnancy but due to staying at home she felt that she was kept in cagewhichshe cant express hence this feeling suppressed to eruptions with itching. This eruption started during her third trimester in first week of seventh month.

ONSET OF ILLNESS- After second trimester when she was prohibited to go out she started with eruptions around stretch marks and then spreads over whole body.

WORK AND SOCIETY- Patient mentioned that because of working women she have many friends always use to enjoy parties with her friends, but due to her father and in laws she afraid that if anyone saw her with her friends they will scold her hence she never dared to went out with her friends.

PRESENT STATE- Patient said now she is happy to have responsibility of her baby so she started to focus on baby by ignoring other tensions. Also expects that her husband and family should also take care of her and her baby to reduce the suppression and change the environment of home.

OBSERVATION-

During interview the patient observed as redness and plethora on face .She looks beautiful with healthy, flabby constitution,continuously looked outside the cabim if someone was there and had to be relaxed by telling no one can hear out.

PHYSICAL GENERALS-

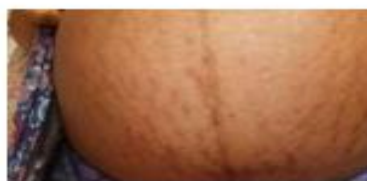Appetite/thirst-Decreased, thirstless
 Craving-spicy, rice,boiled eggs
 Stools/urine-Thin mucus stools and yellowish urine
 Sweat-profuse,forehead3+ ,palms3+
 Sleep-Disturbed and screams during sleep
 Dreams-Ghost and animals,fearful
 Obstretics history-ANC 8th month G1
 Thermal-Chilly
 Menses-Irregularly irregular with dysmennorrhoe during menses
 Sexual function-Desire Decreased since 2 years after marriage
 Past history- PCOD Since 3 years ,hypothyroidism since 6 years
 Family history- NAD

PHYSICAL EXAMINATION-

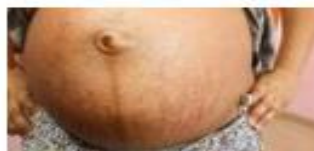Pulse-80/min
 Pallor-+ve
 RS/CVS-NAD
 P/A-NAD

Skin –reddish papules,itchy++

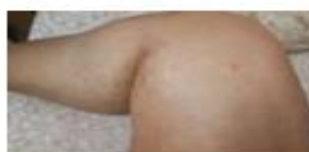PATIENT REPRESENTS CONDITION-



PUPPS AROUND STRECH MARKS ON ABDOMEN



PUPPS ON WHOLE ABDOMEN

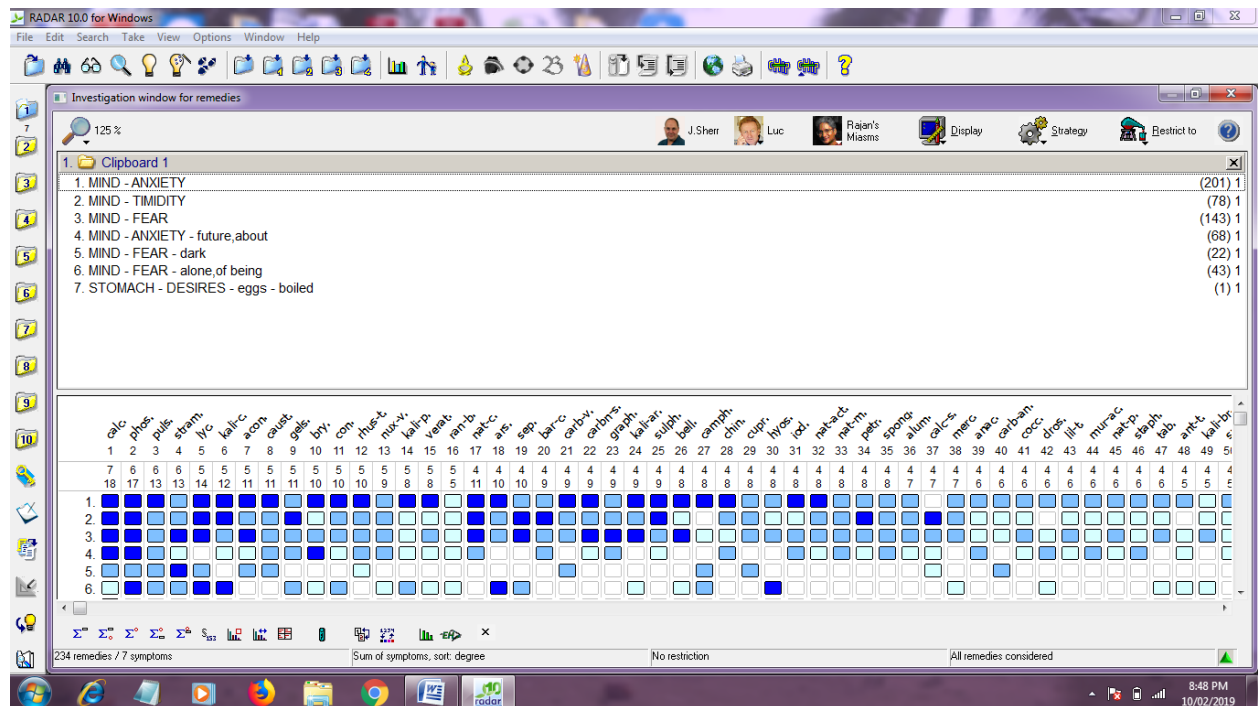


PUPPS ON THIGH AND LEGS

MIND	Physical
A/F ANXIETY	Appearance :lean thin ,beautiful,
ANTICIPATORY	anxious look
TIMIDITY	Sweat: profuse,
FEARSOME 3	forehead3+,palms3+
ANXIETY	Appetite/thirst:Decreased/thirstless
FUTURE ABOUT	
ANXIETY	Craving
CHILDREN ABOUT	
Fear of dark 3,alone	Backache during menses
when3 and animals	aggravation
2 esp snakes and reptiles	
Dreams –fearful3+	Chill with thirst

The case was repertorised and leading to remedies were-calcarea carb and calcarea phos hence case pointed towards calcarea.

Repertorisation sheet



Prescription

Follow up	Date of prescription	Symptom and observation	Prescription
Follow up 1	2 january 2019	Mentally she felt better. Eruptions and rashes subsided 80%.itching still present.	Calcarea 30 3 pills/od for 10days
Follow up 2	12 january 2019	Mentally stable physically 85% relief and eruptions disappear. Itching still present 20%	Sl tds 3-3 pills with calendula soap externally for 10 days
Follow up 3	22 january 2019	Mental and physical both symptoms relieved.	Sl tds 3-3 pills with calendula soap continue
Follow up 4	2 February 2019	No new symptoms recur and patient feels better enjoying pregnancy.	Medicine stopped calendula soap continue till delivery

and improved in a short time with single homoeopathic treatment. The case was cured with remedy without any recurrence of symptoms. There is no specific treatment in other modes of medicine as only homoeopathy does.

REFERENCES

- 1) Kent, J.T. (1997), "lectures on homeopathic philosophy", B.JAIN, PUB(P)LTD. New delhi.
- 2) Textbook of materia medica by Dr. s.k.dubey.
- 3) <http://steemit.com/health/@eileenconneely/a-case-of-pupps-cleared-with-homeopathic-salt>
- 4) <https://www.whattoexpect.com>
- 5) <https://www.everymum.ie/pregnancy/health-and-well-being/what-is-pupps/>.

DISCUSSION AND CONCLUSION: After long history of pupps accompanied with a improvement of mental and emotional plane shows that remedy was correct and safe during pregnancy. The anticipatory anxiety felt was the core of the remedy was correct. Patient was chilly