

Case Report

Coinfection with Cryptosporidium, Isospora and Giardia lamblia in a Patient Living with HIV and AIDS - A Case Report


Arvind Chandora*, Aruna Solanki, P. K. Khatri, Saroj Meena, Archana Bora, Laxmi Rathore, Vinod Maurya, Kanhaiya Lal Sirvi

Department of Microbiology, Dr. S.N. Medical College, Jodhpur (Rajasthan), India

ABSTRACT

A thirty nine year old male positive for Human Immunodeficiency Virus and AIDS, was found to be positive for three different opportunistic parasitic infections. Cryptosporidium, Isospora and Giardia lamblia were simultaneously detected from his stool sample. His CD4 count was 163/cmm. The patient belonged to a village with poor sanitation.

Keywords: Intestinal parasites, AIDS, cryptosporidium isospora, giardia lamblia



QR Code for Mobile Users

Address for Correspondence:

Arvind Chandora

Department of Microbiology,

Dr. S.N. Medical College,

Jodhpur (Rajasthan), India

Conflict of Interest: None declared

(Received 06 July 2015; Accepted 02 August 2015; 1 September 2015) ISSN: 2347-8136 ©2014 JMPI

INTRODUCTION

HIV infection is a significant health problem with most of the cases in Asia and Africa. Globally, India has the highest number of HIV infected people in any single country next only to South Africa. Highest number of AIDS cases has been reported from Tamil Nadu, Maharashtra, Karnataka, Andhra Pradesh, Manipur and Nagaland¹.

Intestinal infection causing diarrheal diseases is a dominant contributor to high death rates and developmental retardation in developing countries². Recently there has been great interest in the impact of HIV on the gut³, both because of virally induced T cell depletion⁴⁻⁶, and because intestinal damage may drive bacterial translocation and hence immune activation.⁷ The presence of opportunistic parasites like Cryptosporidium parvum, Cyclospora cayentensis, Isospora belli, and Microsporidium sp is documented in patients with AIDS.⁸

The incidence and prevalence of infection with a particular enteric parasite in HIV/AIDS patients is likely to depend upon the endemicity of that particular parasite in the community.⁹ As most of

the protozoan infections are treatable, it is important that an early and accurate diagnosis be made.¹⁰

CASE REPORT

A thirty nine year old male patient, a resident of village Tiwari (District Jodhpur), with HIV infection was admitted in medical ward of Infectious Disease Control Institution located at Kamla Nehru Chest Hospital, Jodhpur, with complaints of feverish feeling, diarrhoea, weight loss, nausea and vomiting for four months. Patient was already confirmed for HIV infection as per strategy II of National AIDS Control Organization guideline. Single stool sample was collected on first day in labelled, leak proof, clean sterile plastic containers and were received in the microbiology department. Freshly voided stool specimens were processed using formal-ether concentration technique and examined microscopically under safety technique for examination regarding micro-organisms and ova, cysts or parasites using saline and iodine mounts on grease free slides¹¹.

Sample was subjected to standard parasitological and bacteriological examination. A simple wet

mount preparation revealed few cysts of *Giardia lamblia*. A simple wet mount and a smear stained by modified Z-N staining method were prepared from the concentration material. Wet mount preparation revealed a number of cysts of *Isospora belli* measuring amount 25-30X15-20 μm in size with round granular center. Some of the cysts contained two sporocysts. A smear stained by modified Z-N staining method revealed a large number of round pink cysts of *Cryptosporidium parvum* measuring 4-6 μm in diameter. Oocysts of *Isospora belli* were also observed in the smear.

For bacteriological examination, a smear was prepared and stained by simple Z-N staining method, which did not reveal any acid fast structures or bacilli. The stool sample was also inoculated on the plates of MacConkey agar, nutrient agar and Shigella-Salmonella agar. No pathogenic bacteria were isolated. Thus, the role of bacteria which may cause chronic diarrhoea, i.e, Mycobacteria, Shigella, Salmonella, were ruled out.

Blood CD4 count was 163/cmm.

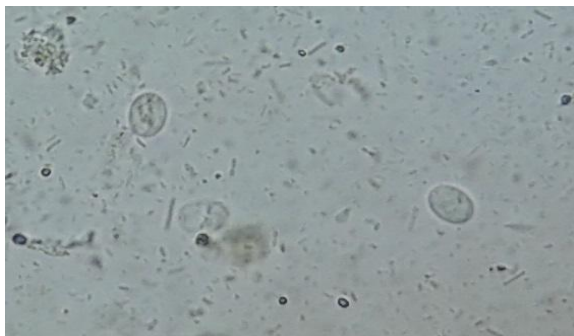


Figure 1: *Giardia lamblia* in wet mount

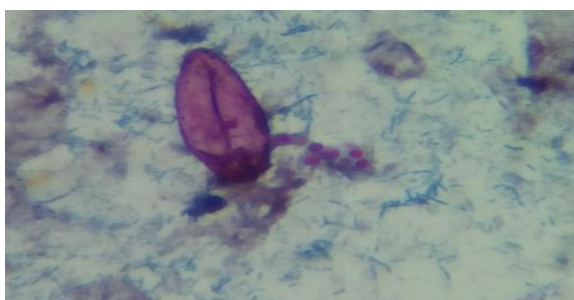

Figure 2: *Isospora belli* and *Cryptosporidium parvum* cyst in modified Z-N Staining

DISCUSSION

Decline in the immunological and the mucosal defensive mechanism predisposes the HIV positive individuals to gastrointestinal infections. Most of the morbidity and mortality in such patients is due to opportunistic infections.¹²

Symptoms Isosporodiosis suggested toxin mediated mechanism but no toxin has been identified¹⁶.

Diarrhoea is one of the most common manifestations in HIV patients and is strongly associated with low CD4+ cell counts. Various studies have shown a rise in diarrhoea caused by parasites which includes both opportunistic agents causing severe form and non-opportunistic agents causing treatable diarrheal illness.¹³

In India,¹⁴ prevalence of *Cryptosporidium* has been found to be about 23% and that of *Isospora belli* infection is about 12% in AIDS patients. *Giardia lamblia* causes heavy infection in AIDS patients with prevalence of about 2.5%. Co-infections with *Cryptosporidium* and *Isospora* as well as *Isospora* and *Giardia lamblia* have been reported from AIDS patients.¹⁵

The patient might acquire multiple parasitic infections because of poor sanitary condition. Although cryptosporidiosis can be acquired at any time during the course of HIV infection, major mortality and morbidity occur almost exclusively in patients with CD4 counts below 180 cells/cmm. Above this level, generally spontaneous recovery occurs. The present case of HIV infection was having a low CD4 count (163/cmm), and this might be responsible for persistent intestinal parasitic infections with chronic diarrhoea. In such patients, frequent stool examination with appropriate concentration techniques may reveal the existence of parasitic infections. In the present case, the mentioned concentration techniques were found very useful for detection of all parasites. These may be useful in early diagnosis and treatment; which will help in improving the quality of life in AIDS patients.

REFERENCES

1. Chan MS, Medley GF, Jamison D, Bundy DAB. The evaluation of potential global morbidity due to intestinal nematode infections. *Parasitology* 1994;109:372-87 (PubMed)
2. Petri WA, Miller M, Binder HJ, Levine MM, Dillingham R, Guerrant RL. Enteric infections, diarrhea, and their impact on function and development. *J Clin Invest* 2008; 118:1277-90
3. Brenchley JM, Douek DC. HIV infection and the gastrointestinal immune system. *Mucosal Immunol* 2008;1:23-30
4. Wang X, Rasmussen T, Pahar B, Poonia B, Alvarez X, Lackner AA, Veazey RS. Massive infection and loss of CD4+ T cells occurs in the intestinal tract of neonatal rhesus macaques in acute SIV infection. *Blood* 2007; 109:1174-81.
5. Lim SG, Condez A, Lee CA, Johnson MA, Elia C, Poulter LW. Loss of mucosal CD4 lymphocytes is an early feature of HIV infection. *ClinExpImmunol* 1993; 92:448-454

6. Schneider T, Jahn HU, Schmidt W, Riecken EO, Zeitz M, Ullrich R. Loss of CD4 lymphocytes in patients infected with HIV type 1 is more pronounced in the duodenal mucosa than in peripheral blood. *Gut* 1995; 37:524-29.
7. Brenchley JM, Price DA, Schacker TW, Asher TE, Silvestri G, Rao S, Kazzaz Z, Bornstein E, Lambote O, Altmann D, Blazar BR, Rodriguez B, Teixeira-Johnson L, Landay A, Martin JN, Hecht FM, Picker LJ, Lederman MM, Deeks SG, Douek DC. Microbial translocation is a cause of systemic immune activation in chronic HIV infection. *Nat Med* 2006; 12:1365-71
8. Goodgame RW. Understanding intestinal sporeforming protozoa: Cryptosporidia, Microsporidia, Isospora and Cyclospora. *Ann Intern Med* 1996; 124:429-41.
9. Mannheimer SB, Soave R. Protozoal infections in patients with AIDS: Cryptosporidiasis, cyclosporiasis and Microsporidiasis. *Infect Dis Clin North Am* 1994; 8: 483-98
10. Curry A, Turner AJ, Lucas S. Opportunistic protozoan infections in human immunodeficiency virus disease: Review highlighting diagnostic and therapeutic agents. *J ClinPathol* 1991; 44:182-193
11. Cheesbrough M. Parasitological tests. Cambridge University Press.1999:pp178-309
12. Escoledo AA, Nunez FA. The prevalence of intestinal parasites in Human Acquired Immunodeficiency syndrome (AIDS) patients. *ActaTropica* 1999; 72:125-30.
13. Uppal B, Kashyap B, Bhalla P. Enteric pathogens in HIV/AIDS from a Tertiary care Hospital. *Indian J Comm Med* 2009;34(3):237-41.
14. Lanjewar DN. Immunopathology of HIV; Proceedings of international symposium on AIDS, Pune, India, May 1995.
15. Ballal M, Prabhu T, Chandran A, Shivananda PG. Cryptosporidium and Isospora belli diarrhoea in immunocompromised host. *Indian J Cancer* 1999;36(1):38-42.
16. Robert W Tolan et al. children's hospital at Saint peter's university hospital.